

NON-ALCOHOLIC STEATOHEPATITIS: ASSOCIATION WITH OBESITY AND INSULIN RESISTANCE, AND INFLUENCE OF WEIGHT LOSS

F.H. LUYCKX (1), P.J. LEFEBVRE (2), A.J. SCHEEN (2)


SUMMARY - Non-alcoholic steatohepatitis (NASH) is a disease of emerging identity and importance, and is now considered as one of the commonest liver diseases in western countries. It is frequently associated with severe obesity, especially abdominal adiposity, and is intimately related to various clinical and biological markers of the insulin resistance syndrome. Especially, both the prevalence and the severity of liver steatosis are related to male sex, body mass index, waist circumference, hyperinsulinaemia, hypertriglyceridaemia and impaired glucose tolerance or type 2 diabetes. A substantial weight loss following gastroplasty is accompanied by a marked reduction in the prevalence and the severity of the various biological abnormalities of the metabolic syndrome and, concomitantly, by an important regression of liver steatosis in most obese patients. However, in some patients, this rapid and drastic weight loss may result in a mild increase in inflammatory lesions (hepatitis), despite the regression of steatosis, which might result from the rapid mobilization of fatty acids or cytokines from adipose tissue, especially visceral fat. The intimate relationship between NASH and obesity leads to the concept that NASH may be considered as another disease of affluence, as is the insulin resistance syndrome and perhaps being part of it.

Key-words: dyslipidaemia, gastroplasty, insulin resistance, liver, NASH, obesity, type 2 diabetes.

RÉSUMÉ - **Stéatohépatite non alcoolique: association avec l'obésité, l'insulinorésistance et influence de la perte de poids.**

La stéatohépatite non alcoolique (NASH) est une maladie dont l'identité et l'importance ont été mises en exergue récemment. Elle est actuellement considérée comme une des hépatopathies les plus fréquentes dans les pays occidentaux. Elle est souvent associée à l'obésité sévère, particulièrement à l'adiposité abdominale, et est intimement liée à divers marqueurs cliniques et biologiques du syndrome d'insulinorésistance. Ainsi, tant la prévalence que la sévérité de la stéatose sont corrélées au sexe masculin, à l'indice de masse corporelle, à la circonférence de la taille, à l'hyperinsulinémie, à l'hypertriglycéridémie et à une diminution de la tolérance au glucose ou un diabète de type 2. Une perte pondérale importante, comme celle observée après une gastroplastie, est associée à une réduction significative de la prévalence et de la sévérité des diverses anomalies biologiques du syndrome métabolique et, concomitamment, à une importante régression de la stéatose chez la plupart des sujets obèses. Cependant, chez certains patients, cet amaigrissement drastique et rapide peut engendrer une légère augmentation des lésions inflammatoires (hépatite), malgré la régression de la stéatose, qui pourrait s'expliquer par la mobilisation massive des acides gras et des cytokines à partir du tissu adipeux, notamment de la graisse viscérale. La relation intime entre la NASH et l'obésité a conduit au concept que la NASH serait une autre « maladie de l'abondance », tout comme le syndrome d'insulinorésistance dont elle pourrait faire partie intégrante.

Mots-clés : dyslipidémie, gastroplastie, insulinorésistance, foie, stéatohépatite non alcoolique, obésité, diabète type 2.

 : A.J. Scheen, Division of Diabetes, Nutrition and Metabolic Disorders, Department of Medicine, CHU Sart Tilman, B-4000 Liège, Belgium.
E-mail: Andre.Scheen@chu.ulg.ac.be

Received : December 31st, 1999

(1) Department of Clinical Chemistry,
(2) Division of Diabetes, Nutrition and Metabolic Disorders, Department of Medicine, CHU Sart Tilman, Liège, Belgium.

The term “non-alcoholic steatohepatitis” (NASH) was coined in 1980 to describe “the pathological and clinical features of non-alcoholic disease of the liver associated with the pathological features most commonly seen in alcoholic liver disease itself” [1]. Analysis of liver biopsy specimens is the cornerstone of diagnosis: hepatic morphological findings range from mild fatty degeneration and inflammation to cell degeneration, fibrosis, and cirrhosis with or without the presence of Mallory hyaline bodies. As recently recognized [2-6], once hepatitis C has been excluded and heavy alcohol consumption is thought unlikely, the diagnosis of persistent abnormalities of liver tests in individuals referred to gastroenterologists and hepatologists in western countries is most probably NASH.

The role of obesity appears to be crucial so that NASH is now considered as “another disease of affluence” [7]. A consensus has emerged that, apart from steatosis, a “second hit” capable of inducing necrosis, inflammation, and fibrosis is required for the development of NASH [7, 8]. Recent studies in animal models and human beings suggested that candidates for this second hit can be grouped into three overlapping categories: 1) factors contributing to oxidative stress and subsequent lipid peroxidation; 2) factors associated with abnormal cytokine production; and 3) factors associated with disordered fatty-acid metabolism and insulin resistance (review in 2-8). While in patients with fatty liver only long-term follow-up suggests a benign, non-progressive course [9], advanced NASH may differ substantially in prognosis and lead to obvious fibrosis and cryptogenic cirrhosis [10].

The present review aims at discussing the role of obesity and metabolic abnormalities associated with insulin resistance (especially diabetes mellitus and dyslipidaemias) in the development of NASH. We will also consider the influence on NASH of a marked and sustained weight loss, such as that obtained in morbidly obese patients after gastric reduction anti obesity surgery.

■ ASSOCIATION OF NASH WITH OBESITY

Obesity is the condition most often associated with NASH as, in most studies, 69% to 100% of patients with NASH were also obese (review in 4). Steatosis is a common observation in obesity and may be associated with inflammatory signs of non-specific hepatitis (*Fig. 1*) [11-13]. In a series of 151 liver biopsies in morbidly obese subjects, some degree of fatty metamorphosis was found in 94% of cases and in 34% over half of the hepatocytes were involved [14]. The pathogenetic mechanisms leading to the accumulation of triglycerides and of fatty acids (FFA) in the hepatocytes can easily be understood from the normal cycling of FFA between the adipose tissue and the

liver [15]. Steatosis may theoretically result from at least one of four processes: 1) increased FFA delivery to the liver; 2) increased FFA synthesis within the liver; 3) insufficient beta-oxidation of FFA; and 4) insufficient very low density lipoprotein synthesis or secretion [2]. Any defect of this multistep process results in accumulation of triglycerides within the hepatocyte, which presents clinically as fatty infiltration of the liver. Whether the accumulation of triglyceride in the liver is responsible for the subsequent inflammatory cell infiltration characteristic of NASH or whether an inflammatory response in the liver evoked by some other stimulus causes sufficient hepatocyte dysfunction to result in steatosis has not been established yet [2, 16]. It has been recently suggested that the high circulating leptin levels associated with obesity may contribute to hepatic steatosis in two ways, by worsening insulin resistance and elevated circulating insulin concentrations and/or by altering insulin signaling in hepatocytes so as to promote increased intracellular accumulation of fatty acids [17]. Furthermore, given the similar intracellular signaling pathways stimulated by leptin and several inflammatory cytokines, leptin may also be involved in the progression from hepatic steatosis to steatohepatitis [17].

Recent observations showed that elevated serum ferritin and iron levels were common findings in patients with NASH (review in 3) and further characterization revealed that about one third of NASH patients had either one or two copies of the Cys282Tyr mutation in the HFE gene (the genetic defect believed to cause haemochromatosis) [18]. Furthermore, it has been demonstrated that increased hepatic iron has the greatest association with the severity of fibrosis. However, body weight was not mentioned in that study [18] and we may speculate that the prevalence of such a mutation is probably higher in nonobese than in obese patients with NASH. Finally, endotoxin and endotoxin-inducible cytokines, including tumor necrosis factor- α (TNF- α) and certain TNF-inducible cytokines, such as interleukins-6 and -8, have also been incriminated, at least in some patients, in the pathogenesis of NASH as in that of alcohol-induced steatohepatitis (review in 3). As TNF- α gene is overexpressed in adipose tissue of obese subjects and in overweight patients with type 2 diabetes, resulting in higher local and circulating TNF- α levels [19], such mechanism should be further investigated in the pathogenesis of NASH associated with obesity and/or type 2 diabetes.

The observation that some obese individuals presented a liver disease histologically indistinguishable from alcoholic liver disease itself had long been recognized [20, 21]. In the previously mentioned series of 151 liver biopsies in morbidly obese patients [14], mild inflammation was observed in 58% and slight periportal fibrosis was detected in 28% of cases (in

addition, early cirrhosis was observed in 4% of the biopsies). In a literature survey of 41 original articles comprising information on liver morphology in 1515 morbidly obese patients, liver biopsy was considered as normal in only 12% of the cases [22]. The most frequent abnormality reported was fatty changes present in 80% of the biopsies; portal inflammation was also common (33%) while portal or periportal fibrosis was observed in 29%. Cirrhosis, however, involved only 3% of the biopsies. These findings were confirmed in more recent studies. In a series of 100 consecutive morbidly obese patients undergoing Roux-en-Y gastric bypass, histologically abnormalities were found in almost all of the examined material (98%), which ranged from mild fatty infiltration through inflammatory change and alcoholic hepatitis-like change to fibrosis and cirrhosis [23]. In a similar study in 50 non-selected obese subjects, normal liver was found in 10%, fatty liver in 48%, fatty hepatitis in 26%, fatty fibrosis in 8% and fatty cirrhosis in 8%, the two latter abnormalities being, however, associated with excessive alcohol intake in most cases [12]. In a

series of liver biopsies in 61 morbidly obese subjects, a high prevalence of fatty changes (85%) and of slight parenchymal (33%) or portal (23%) inflammation was observed, but severe liver damage seemed rare in the absence of alcoholism or diabetes [24]. Finally, in an autopsy study, steatohepatitis was found in 18.5% of markedly obese patients in contrast to only 2.7% of lean patients, while severe fibrosis was found in 13.8% versus 6.6% respectively [25].

We had the opportunity to analyze the liver biopsies in a large series of 528 severely obese subjects (428 females, 100 males; age 36.2 ± 10.5 years, body mass index – BMI – 42.6 ± 6.8 kg/m² – mean \pm SD) submitted to either a vertical ring gastroplasty or an adjustable gastric banding [26]. Subjects with excessive alcohol intake were excluded as candidates to bariatric surgery. As a whole, 74% of the biopsies showed fatty deposition, estimated as mild in 41% of cases, moderate in 32% and severe in 27%. The severity of steatosis was positively associated with BMI ($p = 0.002$), but not with the known duration of obesity.

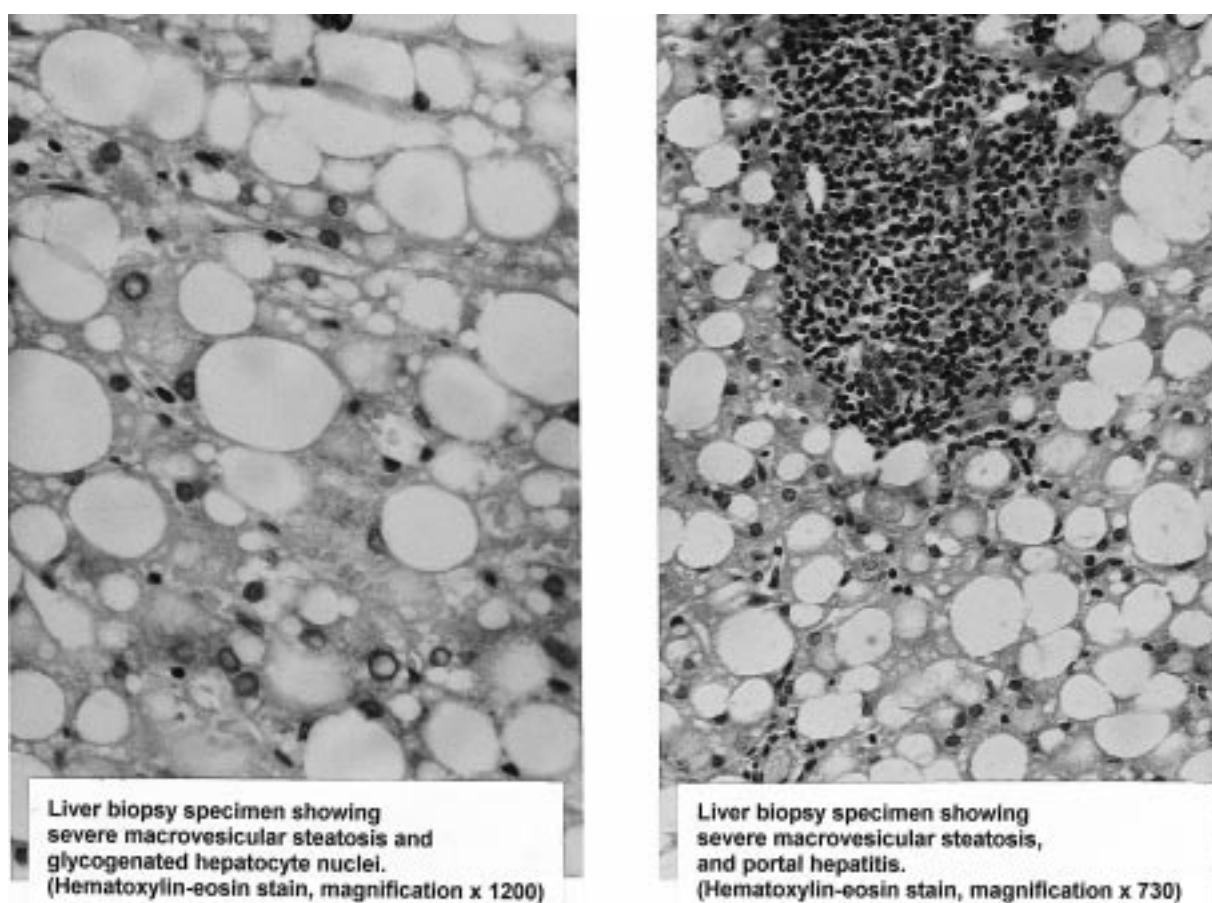


FIG. 1. Illustrations of severe macrovesicular steatosis (left picture) and non-specific steatohepatitis (right picture) in two morbidly obese subjects.

The prevalence of steatosis was higher in men than in women (91% vs 70%, $p < 0.001$) and in patients with impaired glucose tolerance or type 2 diabetes compared to nondiabetics (89% vs 69%, $p < 0.001$). The patients with steatosis had increased serum levels of alanine aminotransferase (ALT), aspartate aminotransferase (AST) and gamma-glutamyl-transpeptidase (gGT) ($p < 0.001$) when compared to obese patients without histologically demonstrated steatosis. The prevalence of abnormal laboratory values progressively increased with the severity of steatosis. As an example, serum ALT levels, the most sensitive liver enzyme, were above upper normal limits in 6% of patients in the absence of steatosis, in 18% of patients with mild steatosis, in 24% of patients with moderate steatosis and in 45% of patients with severe steatosis at liver biopsy ($p < 0.001$). It is noteworthy that fatty liver disease may be observed in obese subjects despite normal serum liver enzyme levels, as pointed out previously [27].

■ ASSOCIATION OF NASH WITH THE INSULIN RESISTANCE SYNDROME AND TYPE 2 DIABETES

One key-feature of obesity, especially visceral obesity, is the presence of insulin resistance in various tissues (liver, skeletal muscle, adipose tissue) [28, 29]. The two metabolic abnormalities most strongly associated with NASH are insulin resistance and an increased supply of fatty acids to the liver. The link between abdominal obesity and liver injury may be explained, especially when resistance to antilipolytic action of insulin is present, by the fact that fatty acids are mobilized more rapidly from visceral (central) than from subcutaneous (peripheral) fat and drained directly to the liver via the portal vein [30]. Excessive intracellular concentrations of fatty acids may be toxic *per se* or lead to oxidative stress, and thus contribute to NASH [4]. In addition, such excessive FFA furniture to and presence in the liver play a major role in the impairment of glucose tolerance leading to type 2 diabetes mellitus [31] and in the high secretion of very-low-density lipoproteins leading to hypertriglyceridaemia and associated dyslipidaemias [32]. Interestingly enough, overexpression and production of TNF- α by adipose tissue has been proposed as an important mechanism of peripheral insulin resistance in obesity and type 2 diabetes [19]. As a potential role of TNF- α has also been proposed in the development of NASH (review in 3), such cytokine might be considered as a common link between these two metabolic abnormalities, especially in subjects with obesity and/or type 2 diabetes.

Decreased insulin sensitivity plays a crucial role in the pathophysiology of type 2 diabetes so that reducing insulin resistance is now considered as a main target in the management of the obese diabetic patient

[33]. Besides obesity, elevated blood glucose values have been noted in 34% to 75% of patients with NASH (review in 4). In type 2 diabetic patients over age 60, the prevalence of fatty liver has been reported to be about 45% [34, 35], whereas fatty liver is rare in subjects with type 1 diabetes. According to several studies, no clear correlation seems to exist between the degree of glucose control or duration of the disease and the fatty infiltration [15, 34, 35]. However, in all cases, diabetic patients with fatty liver are remarkably insensitive to insulin, as already suggested by a pioneer work as early as 1950 [36]. The role of diabetes in producing liver pathology has been controversial although "diabetic hepatitis" has been recognized as a pathological entity [37]. An autopsy study noted a trend toward a higher prevalence of NASH in patients with type 2 diabetes requiring insulin [25]. Another study reported that the distribution of fatty metamorphosis and fibrosis in the morbidly obese patient correlates in severity with the degree of impaired glycaemic status [38]. However, in a recent series, the presence of diabetes mellitus did not differ among patients with either simple fatty liver or more severe lesions such as steatohepatitis, steatonecrosis or fibrosis [39]. So the role of diabetes in the occurrence of NASH remains uncertain.

Insulin resistance is also associated with various metabolic abnormalities, especially dyslipidaemia (hypertriglyceridaemia, low HDL cholesterol, high levels of small dense LDL, postprandial hyperlipidaemia) [32], leading to the concept of "metabolic syndrome", also called "syndrome X" [40]. Hyperinsulinaemia has been long recognized in hepatic steatosis, irrespective of weight excess, and fatty liver has been considered to be associated with relative insulin resistance to which elevated FFA may contribute [41]. Besides obesity, hyperlipidaemia (hypertriglyceridaemia, hypercholesterolaemia, or both) has been reported in 20% to 81% of patients with NASH (review in 4).

In the recent National Health and Nutrition Examination Survey (NHANES-3), 2-6% of the US population surveyed had raised values of serum ALT for which no potential cause of chronic liver disease could be found. Multivariate analysis indicated increased ALT concentration to be significantly and independently associated not only with central obesity (assessed by increased waist/hip ratio) but also with simple indices of insulin resistance (fasting plasma insulin and C-peptide concentrations) and haemoglobin A_{1c} levels (cited in 7).

Marceau *et al.* [42] recently reported on the frequent association between the metabolic syndrome observed in severe obesity and liver pathology. In 551 liver biopsies performed in severely obese patients undergoing antiobesity surgery, steatosis was found in 86%, fibrosis in 74%, mild inflammation or steatohepatitis in 24%, and unexpected cirrhosis in 2% of the patients. Interestingly enough, with each addition

of 1 of the 4 following components of the metabolic syndrome (elevated waist/hip ratio, impaired glucose tolerance, hypertension, and dyslipidaemia), the risk of steatosis increased exponentially from 1- to 99-fold ($p < 0.001$) (Table I). Furthermore, patients with impaired glucose tolerance or diabetes had a 7-fold increased risk of fibrosis ($p < 0.0001$). Thus, this study confirmed earlier observations demonstrating that the severity of NASH in the morbidly obese patient correlates in severity with the degree of impaired glycaemic status [38].

Knobler *et al.* [43] have evaluated 48 consecutive patients referred to their gastroenterology unit for chronically (> 6 months) raised liver enzyme levels with clinical, ultrasound, and histological findings consistent with fatty infiltration of the liver and no data suggesting any specific cause. Most patients (81%) were overweight or obese and had increased waist circumference, which closely relates to visceral fat and insulin resistance. Type 2 diabetes was found

TABLE I. Comparison between demographic data, liver biopsy findings and biological abnormalities in morbidly obese subjects studied before bariatric surgery by Marceau *et al* [42] and by our group [26, 44].

	Marceau et al	Our study
Demographic data		
N	531	528
Sex (F/M)	439/112	428/100
Age (years)	36 ± 9	36 ± 10
BMI (kg/m ²)	47 ± 9	43 ± 7
Diabetes (%)	10	17*
Hypertension (%)	41	39
Liver biopsy data		
Steatosis (%)	86	74
Steatohepatitis (%)	24	10
Biological data		
Elevated liver enzymes (%)	4-20	14-35
Fasting plasma glucose > 6 mmol/l (%)	28	34
Fasting triglycerides > 3 mmol/l (%)	14	12
Cholesterol abnormalities (%)**	46	42

*: Impaired glucose tolerance was included in our study. **: Total cholesterol/HDL ratio > 5 in Marceau's study; low HDL cholesterol in our study.

in 44% of the subjects, 29% had impaired glucose tolerance, and 17% were hyperinsulinaemic. Furthermore, 85% had hypertriglyceridaemia, low serum HDL cholesterol concentration, or both. Dietary intervention resulting in a moderate weight loss (only 3.7 kg), supplemented by oral hypoglycaemic or lipid-lowering drugs as needed (statins or fibrates have been used in some patients of this study and were well tolerated), decreased fasting blood glucose and improved serum lipid profile after a median 24-month follow-up. A substantial reduction in serum liver enzymes was observed in almost all subjects (96%) with normalization of liver profile in a majority of patients.

In a large series of 505 severely obese subjects evaluated before gastroplasty, we estimated various biological parameters classically associated with the insulin resistance syndrome [44] and we attempted to correlate biological abnormalities with both presence and severity of steatosis [26]. When compared with patients without fatty liver deposition, those with liver steatosis had significantly higher fasting plasma glucose (5.5 mmol/l vs 5.1 mmol/l, $p = 0.007$), insulin (144 pmol/l vs 90 pmol/l, $p = 0.003$), triglycerides (1.8 mmol/l vs 1.3 mmol/l, $p = 0.002$) and ALT (28 UI/l vs 17 UI/l, $p = 0.001$) levels. The severity of the steatosis was positively correlated, not only to BMI ($p = 0.002$), but also to fasting plasma glucose ($p < 0.001$), insulin ($p < 0.01$) and triglycerides ($p < 0.001$) concentrations as well as to serum ALT ($p < 0.001$), AST ($p < 0.001$) and gamma-GT ($p < 0.005$) levels (Fig. 2). Thus, our observations confirmed those of Marceau *et al.* [42] (Table I) and suggested a close relationship between liver steatosis and insulin resistance syndrome in morbidly obese subjects.

■ INFLUENCE OF WEIGHT LOSS ON BOTH NASH AND INSULIN RESISTANCE SYNDROME

Because obesity is the condition most commonly associated with NASH, weight loss is frequently advocated [4]. However, weight loss is difficult to evaluate because obese patients with NASH rarely achieve or maintain sustained reductions in weight. Moreover, the effect of weight loss on liver disease is not consistent (review in 3-5). While histological lesions of steatohepatitis deteriorates after rapid weight loss [45, 46], improvement generally occurs after gradual weight reduction [47, 48]. The effects of losing weight on liver function and morphology may also vary according to the way of obtaining weight reduction. In obese patients treated by prolonged fasting or low-calorie dieting, a transient increase in the degree of hepatocellular degeneration and focal necrosis along with progressive diminution of fatty infiltration was observed during acute weight loss, but late biopsies revealed histologically normal livers [49]. In contrast, in obese patients treated by intestinal bypass surgery,

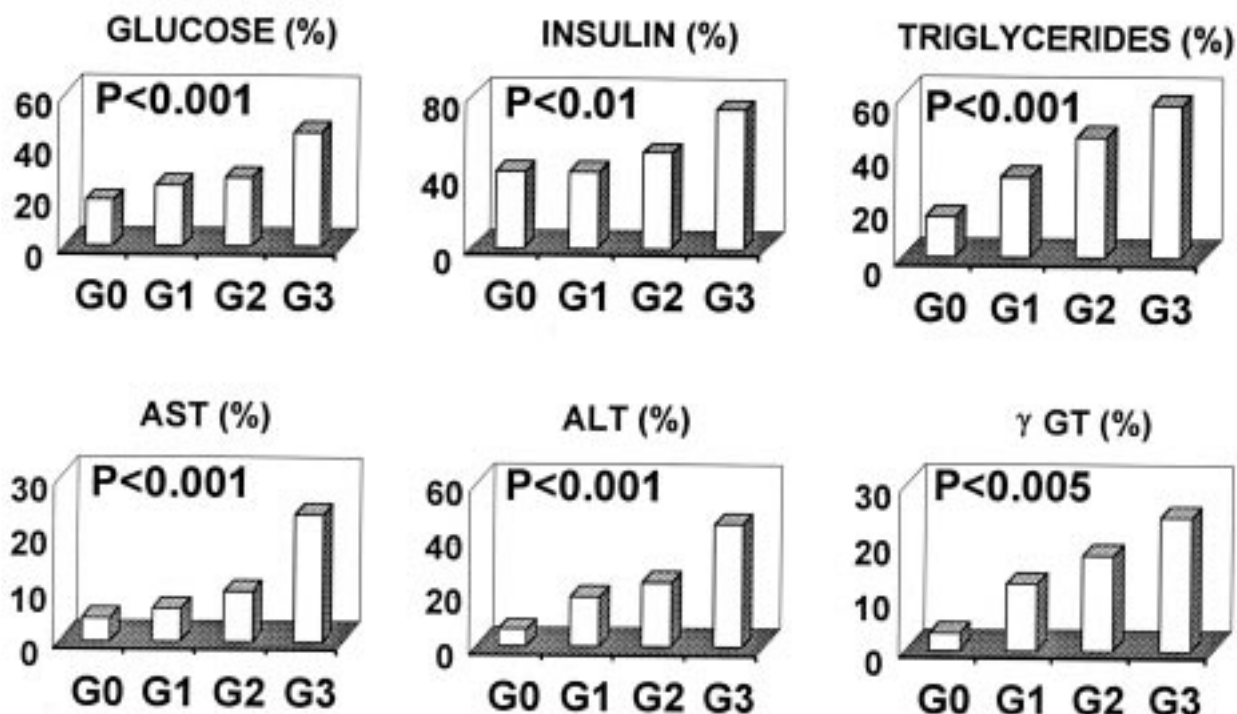


FIG. 2. Relationships between the degree of steatosis (grade 0: no steatosis; grade 1: mild steatosis; grade 2: moderate steatosis; grade 3: severe steatosis) and the prevalence (%) of high levels of three markers of insulin resistance (fasting plasma glucose, plasma insulin, and serum triglycerides) and of three serum liver enzymes (ALT, AST and gamma-GT) in a large cohort of severely obese subjects (reference 26).

major morphological changes may occur with massive fatty changes, cholestasis, polynuclear inflammatory infiltrates, diffuse fibrosis, bile-duct proliferation and fatal hepatic necrosis [49]. During the 1970s, NASH was encountered as a common complication of jejunioileal bypass (JIB) surgery for morbid obesity [50, 51]. Liver dysfunction occurred in 40% of obese patients who underwent jejunal bypass surgery for weight reduction [52], and in 2.2% to 6% of these patients, evidence of liver failure appeared during the first 12 to 18 months, when weight loss was most rapid [4]. Several studies pointed out that deranged architecture is similar to that of the alcoholic liver lesions, which suggests common pathogenetic mechanisms [53, 54]. In fact, the pathogenesis of NASH after jejunal bypass in morbidly obese patients appears to be multifactorial: potential mechanisms include absorption of bacterial products or bile acids from the blind loop, severe protein malnutrition and massive mobilization of FFAs during weight loss (review in 4).

Besides this specific toxic effect of intestinal bypass, the effect of weight loss on liver function and morphology appears more favourable, although it remains controversial. It is still considered that sudden weight loss or weight cycling — increasingly encountered because of dieting — may predispose to NASH (cited in 7). A rapid weight loss of 34 ± 9 kg with a

very-low-calorie formula diet resulted in a significant improvement of fatty change ($p < 0.001$), but 24% of the patients developed slight portal inflammation or fibrosis [46]. Interestingly, patients developing portal fibrosis had a higher degree of fatty change before dieting, a more pronounced reduction of fatty change and a faster weight loss. Early studies demonstrated that weight reduction due to fasting or low calorie diets are associated with reduced steatosis [55, 56]. In overweight patients without primary liver disease, a weight reduction of $> 10\%$ corrected abnormal hepatic test results, decreased hepatosplenomegaly, and resolved some stigmata of liver disease [57]. In a pilot study where livers of morbidly obese subjects were examined after gastric bypass as well as beforehand, there was a decrease in the degree of steatosis 12 to 18 months afterwards [58]. In a small series of 15 obese subjects, the occurrence of steatosis decreased from 73 to 40% one year after gastroplasty or gastric bypass together with a marked decrease in individual gradings of fatty changes and a disappearance of initial discrete inflammatory or granulomatous changes [59]. In a larger series of 91 patients followed from 2 to 61 months after gastric bypass with gastrojejunostomy, liver biopsies showed that 65 patients had reduced steatosis, 18 patients with no or only minimal steatosis had no change, and 3 patients had increased steatosis.

Pre-gastric bypass biopsies showed perisinusoidal fibrosis in 13 patients which disappeared afterwards in 10 patients, was reduced in one patient and remained unchanged in two patients; only one patient developed such abnormal histological findings after gastric bypass [60]. Thus, in contrast to what was reported with jejunioileal bypass, gastric bypass resulted in a reduction or elimination of most hepatic fatty change and some perisinusoidal fibrosis after a major weight loss.

In our large cohort of severely obese subjects submitted to a gastroplasty, a regular clinical follow-up was organized after bariatric surgery [44]. Body weight measurements and biological data were obtained in 505 patients (419 females, 86 males; age 36 ± 11 years; BMI 42.7 ± 6.9 kg/m²) with a mean follow-up of 26 ± 14 months. At baseline, the population was characterized by a high prevalence of biological abnormalities linked to the metabolic syndrome. After a mean weight loss of 32 ± 16 kg, a remarkable improvement in the biological profile was observed, with significant reductions in mean plasma glucose, insulin and fibrinogen levels, as well as in serum triglycerides and uric acid concentrations; concomitantly, a significant increase in mean serum HDL cholesterol levels was noticed [44]. Mean serum ALT levels also diminished by 14% ($p < 0.01$) [26]. These reductions in mean values were accompanied by a significant diminution in the prevalence of all these biological abnormalities as shown in Table II. Interestingly enough, especially regarding the recent speculation about a potential role of leptin in obesity-associated liver disease [17], hyperleptinaemia was also markedly reduced after weight loss (from 44.7 ng/ml at a mean BMI of 40.7 kg/m² before gastroplasty to 21.7 ng/ml at a mean BMI of 32.5 kg/m² 6 months after gastroplasty, $n = 38$, $p < 0.001$). Thus, the drastic weight loss associated with gastroplasty induced a remarkable reduction in the prevalence and severity of all biological abnormalities classically considered as markers of syndrome X and cardiovascular risk factors. In addition, we could demonstrate in a subset of 8 severely obese women that the recovery of ideal body weight following gastroplasty resulted in a full normalization of the abnormalities in insulin secretion, clearance and action on glucose metabolism, and thus in a complete reversal of insulin resistance and compensatory hyperinsulinaemia [61]. Finally, we showed in a subgroup of 24 morbidly obese patients with type 2 diabetes that glucose control was significantly improved after gastroplasty-associated weight reduction: HbA_{1c} levels were almost normalized despite a significant reduction of antidiabetic oral agents or insulin doses [62]. All these metabolic improvements related to weight reduction may favourably influence NASH of obese subjects.

Interestingly enough, 69 patients of the initial cohort submitted to a first biopsy before gastroplasty had a second liver biopsy 27 ± 15 months after bariatric

surgery, in the course of a mandatory surgical procedure (complications of initial surgical procedure or cholecystectomy) [26]. After a mean weight loss of 32 ± 19 kg, a remarkable decrement in liver fatty scores was observed: 45% of the biopsies were considered as normal (vs 13% at baseline, $p < 0.001$) while pure fatty change was still observed in only 38% of the patients (vs 83% before, $p < 0.001$) (Table II). In addition, the severity of the steatosis was significantly ($p < 0.001$) reduced (mild: 62% vs 21%; moderate: 23% vs 37%; severe: 15% vs 42%). This reduction in the prevalence and severity of liver steatosis was associated with a significant diminution of serum ALT levels ($p = 0.02$) [26]. Such regression of steatosis occurred even in absence of weight normalization. Thus, our observations demonstrated a parallel reversibility of biological disturbances related to the metabolic syndrome and liver steatosis after gastroplasty-induced weight loss in severe obesity, suggesting a causal relationship or, at least, a common feature between these two abnormalities [63, 64]. However, a slight but significant increase in the prevalence of hepatitis was observed after pronounced weight reduc-

TABLE II. Prevalence (%) of abnormal biological values related to the metabolic syndrome in 505 obese subjects and of abnormal liver biopsies in a subgroup of 69 obese subjects before and about 2 years after gastroplasty and a substantial weight loss of about 30 kg (adapted from references 26 and 44).

Parameters	Before weight loss (%)	After weight loss (%)	p
Biological markers (n = 505)			
Hyperinsulinaemia	58	32	0.004
Hyperglycaemia	35	21	0.004
Hypertriglyceridaemia	44	24	0.005
Low HDL cholesterol	44	35	0.05
Hyperfibrinogenaemia	43	20	0.003
Hyperuricaemia	15	9	0.04
Elevated serum ALT	35	21	0.01
Liver biopsies (*) (n = 69)			
Normal	13	45	0.001
Steatosis	83	38	0.001
Hepatitis	14	26	0.05
Fibrosis or cirrhosis	1.5	1.5	NS

(*)Some liver biopsies may present several abnormalities, especially hepatitis in addition to steatosis.

tion (26% of the biopsies after gastroplasty vs 14% before, $p < 0.05$) [26]. Considering the potential deleterious effect of fatty acids [7, 8, 16], our data may suggest that the rapid mobilization of intra- and extra-hepatic stores induced by drastic weight loss following bariatric surgery, perhaps in association with some deficient protein intake, may be toxic for the liver and result in mild lobular hepatitis in some patients. As already discussed, a potential toxic role of cytokines, especially TNF- α which is overexpressed and produced in excess by adipocytes of obese subjects, deserves also further investigations [7].

CONCLUSIONS

Liver steatosis is a common feature in severely obese subjects and is especially associated with visceral adiposity and diabetic status. A positive relationship is observed with classical biological markers of the metabolic syndrome, such as hyperinsulinaemia and hypertriglyceridaemia. Most importantly, we demonstrated that post-gastroplasty weight loss results in a significant improvement of both insulin sensitivity and biological abnormalities of the metabolic syndrome and, in a parallel fashion, is associated with a marked reduction in both prevalence and severity of liver steatosis, but in some cases, at the expense of steatohepatitis. However, the latter histological abnormality observed after drastic weight loss following gastroplasty (or gastric bypass) is mild and not comparable at all with the severe and sometimes fatal hepatic complications reported after jejunoileal bypass. Recent data of the literature and personal observations led to the new concept that NASH should be considered as being part of the insulin resistance syndrome. Thus, both NASH and metabolic syndrome associated with severe obesity are common markers of a so-called disease of affluence.

Acknowledgements – We thank Prof Dr C. Desaive from the Department of Surgery and Dr A. Thiry from the Department of Anatomopathology, CHU Sart Tilman, Liège, Belgium, for their valuable help in collecting and analyzing the original liver biopsy specimens supporting the present review.

REFERENCES

- Ludwig J, Viggiano TR, McGill DB, Ott B. Nonalcoholic steatohepatitis: Mayo clinic experiences with a hitherto unnamed disease. *Mayo Clin Proc*, 1980, 55, 434-438.
- Bacon BR, Farahvash MJ, Janney CG, Neuschwander-Tetri BA. Non-alcoholic steatohepatitis: an expanded clinical entity. *Gastroenterology*, 1994, 107, 1103-1109.
- Diehl AM. Nonalcoholic steatohepatitis. *Semin Liver Dis*, 1999, 19, 221-229.
- Sheth SG, Gordon FD, Chopra S. Nonalcoholic steatohepatitis. *Ann Intern Med*, 1997, 126, 137-145.
- Ludwig J, McGill DB, Lindor KD. Review: Non alcoholic steatohepatitis. *J Gastroenterol Hepatol*, 1997, 12, 398-403.
- James OFW, Day CP. Non-alcoholic steatohepatitis (NASH): a disease of emerging identity and importance. *J Hepatol*, 1998, 29, 495-501.
- James O, Day C. Non-alcoholic steatohepatitis: another disease of affluence. *Lancet*, 1999, 353, 1634-1636.
- Day CP, James OFW. Steatohepatitis: a tale of two "hits"? *Gastroenterology*, 1998, 114, 842-845.
- Telli MR, James OFW, Burt AD, Bennett MK, Day CP. The natural history of non-alcoholic fatty liver: a follow-up study. *Hepatology*, 1995, 22, 1714-1719.
- Caldwell SH, Oelsner DH, Lezzoni JC, Hennesheide EE, Battle EH, Driscoll CJ. Cryptogenic cirrhosis: clinical characterization and risk factors for underlying disease. *Hepatology*, 1999, 29, 664-669.
- Zelman S. The liver in obesity. *Arch Intern Med*, 1952, 90, 141-156.
- Braillon A, Capron JP, Hervé MA, Degott C, Quenum C. Liver in obesity. *Gut*, 1985, 26, 133-139.
- Clain D, Lefkowitz J. Fatty liver disease in morbid obesity. *Gastroenterol Clin North Am*, 1987, 16, 239-252.
- Kern WH, Heger AH, Payne JH. Fatty metamorphosis of the liver in morbid obesity. *Arch Pathol*, 1973, 96, 342-346.
- Van Steenberghe W, Lanckmans S. Liver disturbances in obesity and diabetes mellitus. *Int J Obesity*, 1995, 19 (Suppl 3), S27-S36.
- Day CP, James OFW. Hepatic steatosis — innocent bystander or guilty party? *Hepatology*, 1998, 27, 1463-1466.
- Kaplan LM. Leptin, obesity, and liver disease. *Gastroenterology*, 1998, 115, 997-1001.
- George DK, Goldwurm S, MacDonald GA *et al*. Increased hepatic iron concentration in nonalcoholic steatohepatitis is associated with increased fibrosis. *Gastroenterology*, 1998, 114, 311-318.
- Hotamisligil GH, Spiegelman BM. Tumor necrosis α . A key component of the obesity-diabetes link. *Diabetes*, 1994, 43, 1271-1278.
- Alder M, Schaffner F. Fatty liver hepatitis and cirrhosis in obese patients. *Am J Med*, 1979, 67, 811-816.
- Manes JL, Taylor HB, Starkloft GB. Relationship between hepatic morphology and clinical and biochemical findings in morbidly obese patients. *J Clin Pathol*, 1973, 26, 776-783.
- Andersen T, Gluud C. Liver morphology in morbid obesity: a literature survey. *Int J Obesity*, 1984, 8, 97-106.
- Klain J, Fraser D, Goldstein J *et al*. Liver histology abnormalities in the morbidly obese. *Hepatology*, 1989, 10, 873-876.
- Andersen T, Christoffersen P, Gluud C. The liver in consecutive patients with morbid obesity: a clinical, morphological, and biochemical study. *Int J Obesity*, 1984, 8, 107-115.
- Wanless IR, Lentz JS. Fatty liver steatosis (steatohepatitis) and obesity: an autopsy study with analysis of risk factors. *Hepatology*, 1990, 12, 1106-1110.
- Luyckx FH, Desaive C, Thiry A *et al*. Liver abnormalities in severely obese subjects: effects of drastic weight loss after gastroplasty. *Int J Obesity*, 1998, 22, 222-226.
- Galambos JT, Wills CE. Relationship between 505 paired liver tests and biopsies in 242 obese patients. *Gastroenterology*, 1978, 74, 1191-1195.
- Scheen AJ, Paquot N, Letiexhe M, Paolisso G, Castillo MJ, Lefèbvre PJ. Glucose metabolism in obesity: lessons from OGTT, IVGTT, and clamp studies. *Int J Obesity*, 1995, 19 (Suppl 3), S14-S20.
- Scheen AJ, Lefèbvre PJ. Insulin action in man. *Diabetes Metab*, 1996, 22, 105-110.
- Kissebah AH, Krakower GR. Regional adiposity and morbidity. *Physiol Rev*, 1994, 7, 761-811.
- Boden G. Role of fatty acids in the pathogenesis of insulin resistance and NIDDM. *Diabetes*, 1997, 45, 3-10.
- Howard BV. Insulin resistance and lipid metabolism. *Am J Cardiol*, 1999, 84 (Suppl 1A), 28J-32J.
- Scheen AJ, Lefèbvre PJ. Management of the obese diabetic patient. *Diabetes Rev*, 1999, 7, 77-93.
- Creutzfeldt W, Frerichs H, Sickinger K. Liver diseases and diabetes mellitus. *Prog Liver Dis*, 1970, 3, 371-407.
- Stone BG, Van Thiel DH. Diabetes mellitus and the liver. *Semin Liver Dis*, 1985, 5, 8-28.
- Zimmerman HJ, MacMurray FG, Rappaport H, Alpert IK. Studies of the liver in diabetes mellitus. II. The significance of fatty metamorphosis and its correlation with insulin insensitivity. *J Lab Clin Med*, 1950, 36, 922-927.

- 37 Nagore N, Scheuer PJ. The pathology of diabetic hepatitis. *J Pathol*, 1998, 156, 155-160.
- 38 Silverman JF, O'Brien KF, Long S et al. Liver pathology in morbidly obese patients with and without diabetes. *Am J Gastroenterol*, 1990, 85, 1349-1355.
- 39 Matteoni CA, Younossi ZM, Gramlich T, Boparai N, Liu YC, McCullough AJ. Nonalcoholic fatty liver disease: a spectrum of clinical and pathological severity. *Gastroenterology*, 1999, 116, 1413-1419.
- 40 Reaven GM. Role of insulin resistance in human disease. *Diabetes*, 1988, 37, 1595-607.
- 41 Oehler G, Bleyl H, Matthes KJ. Hyperinsulinemia in hepatic steatosis. *Int J Obesity*, 1982, 6 (Suppl 1), 137-144.
- 42 Marceau P, Biron S, Hould FS, et al. Liver pathology and the metabolic syndrome X in severe obesity. *J Clin Endocrinol Metab*, 1999, 84, 1513-1517.
- 43 Knobler H, Schattner A, Zhomicki T, et al. Fatty liver — an additional and treatable feature of the insulin resistance syndrome. *Q J Med*, 1999, 92, 73-79.
- 44 Luyckx FH, Scheen AJ, Desai C, Dewé W, Gielen JE, Lefèbvre PJ. Effects of gastroplasty on body weight and related biological abnormalities in morbid obesity. *Diabetes Metab*, 1998, 24, 355-361.
- 45 Capron JP, Delamarre J, Dupas JL, Braillon A, Degott C, Quenum C. Fasting in obesity: another cause of liver injury with alcoholic hyaline? *Dig Dis Sci*, 1982, 27, 265-268.
- 46 Andersen T, Gluud C, Franzmann MB, Christoffersen P. Hepatic effects of dietary weight loss in morbidly obese subjects. *J Hepatology*, 1991, 12, 224-229.
- 47 Eriksson S, Eriksson KF, Bondesson L. Nonalcoholic steatohepatitis in obesity: a reversible condition. *Acta Med Scand*, 1986, 220, 83-88.
- 48 Keeffe EB, Adesman PW, Stenzel P, Palmer RM. Steatosis and cirrhosis in an obese diabetic. Resolution of fatty liver by fasting. *Dig Dis Sci*, 1987, 32, 441-445.
- 49 Drenick EJ, Simmons F, Murphy JF. Effect on hepatic morphology of treatment of obesity by fasting, reducing diets and small-bowel bypass. *N Engl J Med*, 1970, 282, 829-834.
- 50 Brown RG, O'Leary JP, Woodyard ER. Hepatic effects of jejunioleal bypass for morbid obesity. *Am J Surg*, 1974, 127, 53-58.
- 51 Ames FC, Copeland EM, Leeb DC, Moore DL, Dudrick SJ. Liver dysfunction following small-bowel bypass for obesity. *JAMA*, 1976, 235, 1249-1252.
- 52 McFarland RJ, Gazet JC, Pilkington TR. A 13-year review of jejunioleal bypass. *Br J Surg*, 1985, 72, 81-87.
- 53 Peters RL. Patterns of hepatic morphology in jejunioleal bypass patients. *Am J Clin Nutr*, 1977, 30, 53-57.
- 54 Vyberg M, Ravn V, Andersen B. Pattern of progression in liver injury following jejunioleal bypass for morbid obesity. *Liver*, 1987, 7, 271-276.
- 55 Berkovitz D. Metabolic changes associated with obesity before and after weight reduction. *JAMA*, 1964, 187, 399-403.
- 56 Rozental P, Biava C, Spencer H, Zimmerman HJ. Liver morphology and function tests in obesity and during total starvation. *Am J Dig Dis*, 1967, 12, 198-207.
- 57 Palmer M, Schaffner F. Effect of weight reduction on hepatic abnormalities in overweight patients. *Gastroenterology*, 1990, 99, 1408-1411.
- 58 Halverson JD, Zuckerman GR, Koehler RE, et al. Gastric bypass for morbid obesity: A medical-surgical assessment. *Ann Surg*, 1981, 194, 152-160.
- 59 Ranlov I, Hardt F. Regression of liver steatosis following gastroplasty or gastric bypass for morbid obesity. *Digestion*, 1990, 47, 208-214.
- 60 Silverman EM, Sapala JA, Appelman HD. Regression of hepatic steatosis in morbidly obese persons after gastric bypass. *Am J Clin Pathol*, 1995, 104, 23-31.
- 61 Letiexhe MR, Scheen AJ, Gérard PL, Desai C, Lefèbvre PJ. Post-gastroplasty recovery of ideal body weight normalizes glucose and insulin metabolism in obese women. *J Clin Endocrinol Metab*, 1995, 89, 393-399.
- 62 Scheen AJ. Aggressive weight reduction treatment in the management of type 2 diabetes. *Diabetes Metab*, 1998, 24, 116-123.
- 63 Luyckx FH, Scheen AJ, Desai C, Thiry A, Lefèbvre PJ. Parallel reversibility of biological markers of the metabolic syndrome and liver steatosis after gastroplasty-induced weight loss in severe obesity (Letter). *J Clin Endocrinol Metab*, 1999, 84, 4293.
- 64 Luyckx FH, Scheen AJ, Lefèbvre PJ. Non-alcoholic steatohepatitis (Letter). *Lancet*, 1999, 354, 1298-1299.